

## Coordinated expression in chronically unconscious persons

F. Plum, N. Schiff, U. Ribary and R. Llinás

*Phil. Trans. R. Soc. Lond. B* 1998 **353**, 1929-1933  
doi: 10.1098/rstb.1998.0345

### References

Article cited in:

<http://rstb.royalsocietypublishing.org/content/353/1377/1929#related-urls>

### Email alerting service

Receive free email alerts when new articles cite this article - sign up in the box at the top right-hand corner of the article or click [here](#)

To subscribe to *Phil. Trans. R. Soc. Lond. B* go to: <http://rstb.royalsocietypublishing.org/subscriptions>

# Coordinated expression in chronically unconscious persons

Fred Plum<sup>1</sup>, Nicholas Schiff<sup>1</sup>, Urs Ribary<sup>2</sup> and Rodolfo Llinás<sup>2</sup>

<sup>1</sup>Cornell University Medical College, New York Presbyterian Hospital, 1300 York Avenue, NY 10021, USA

<sup>2</sup>Center for Neuromagnetism, New York University School of Medicine, 550 First Avenue, NY 10016, USA

The clinically described 'persistent vegetative state' (PVS), consists of wakefulness unaccompanied by any evidence of the subject's awareness of self or environment. Past studies from our own and other laboratories have used positron emission tomography (PET) to study brain metabolism in approximately 20 such patients during wakeful periods. All those efforts identified global cerebral glucose metabolism at or below levels encountered during deep barbiturate anaesthesia. Nevertheless, the clinical literature includes rare reports of relatively isolated cognitive functions expressed by PVS patients late in their course. The observation raises the question of whether such activity reflects awareness or unconscious automatic behaviour. We employed magnetometry (MEG), PET scanning, MR imaging and 24-hour EEG recordings to evaluate three patients clinically vegetative between six months and 20 years after onset.

Neither meticulous clinical examinations nor 24-hour EEG and video monitoring provided any hint of cognitive interaction in any subject. Nevertheless, patient 1 uttered single words once every 48 hours or more; patient 2 frequently expressed coordinated, non-purposeful, non-dystonic movements in arms and/or legs; and, patient 3 expressed strong emotional negativity without motor responses to noxious stimuli with occasional quieting in response to prosodic stimuli.

All patients had whole-brain averaged global metabolism levels below 50% of normal. Patient 1, however, demonstrated preserved islands of increased metabolism in the posterior frontal and posterior temporal lobes, as well as MEG activations of Heschl's gyrus all located in the left hemisphere. In patient 2, selected increased metabolism was confined to the frontal poles and related subcortical structures. MRI in patient 3 demonstrated severe, bilateral post-traumatic cerebral atrophy. PET metabolism was diffusely reduced to 40% of normal but MEG evoked potentials indicated early and late sensory processing with abnormal later evoked components.

The correlation of fragmentary behaviour with preserved metabolic and physiologic activity in cortical and subcortical regions known to support specific modular functions is novel. The finding demonstrates the capacity of severely damaged brains to partially express surviving modular functions without evidence of integrative processes that would be necessary to produce consciousness.

We conclude that the mere expression of isolated neuropsychologic activity by isolated modules is insufficient to generate consciousness in overwhelmingly damaged brains.

**Keywords:** vegetative; unconscious; isolated modules; MEG; PET; MRI

## 1. INTRODUCTION

The human vegetative state defines a clinical-cognitive syndrome represented by endogenous sleep-wake cycles devoid of any evidence of conscious awareness during awake periods. Its most common causes consist of severe acute head trauma, acute hypoxia-asphyxia or severe acute or chronic medical illnesses that diffusely damage the cerebrum. Customarily, the term is applied to acutely affected patients only after a period of several days or more after onset. However, the longer the state lasts the more it indicates the likelihood of future permanent brain dysfunction. Jennett & Plum (1972) arbitrarily coined and applied the term persistent vegetative state (PVS) to patients who remained vegetative for more than one month following either brain trauma or severe neurologic disease. Any duration longer than a month increasingly risks the occur-

rence of severe brain dysfunction in subsequent survivors. For example, the Multi-Society Task Force (1994), examining the medical aspects of PVS, calculated that among 434 adults still vegetative at one month following the onset of brain trauma, only 24% regained a moderate to good outcome. Among 169 patients in PVS following severe medical illness only 4% reached a similar level of recovery. Outcomes for PVS lasting three months were significantly worse: only 16% of trauma survivors regained moderate to good function, whereas only 1% of the non-traumatic group achieved a similarly high level of recovery.

How did the vegetative state get its name? Not as the reader might think. Patients' families sometimes challenge us, implying that we have regarded the sufferer as a vegetable. Not so! The conception of a vegetative nervous system goes a long way back. Bichat (1800) divided the nervous system into two parts, one of which he termed

the animalic; this linked the person to his/her environment and was expressed by the muscles of voluntary locomotion and the organs of external senses. The other, identified as transacting the nutritional functions of the body, Bichat termed the vegetative component of the nervous system. As neurology evolved during the next hundred years and particularly during the decades straddling the late 19th and early 20th centuries, increasing attention was addressed to autonomic adrenergic and cholinergic systems that regulated cardiovascular, respiratory and visceral organ systems. Taken in total, the results were described within Bichat's concept of the vegetative nervous system. Indeed, the Ninth Annual Proceedings of the Association of Nervous and Mental Disease (Timme *et al.* 1928) was titled, 'The vegetative nervous system: an investigation of the most recent answers'. Jennett & Plum (1972) recalled this convenient term which separated the presence of still active bodily neuro-visceral systems from their losses of all cognitive processes. In present circumstances, the meaning of PVS is widely understood but, unfortunately, few physicians or even neuroscientists understand that the now obsolete term, vegetative, was once the proud generic describer of the remarkable intricacies of the autonomic nervous system and its endocrinological associations.

What has not been identified as this report indicates, is that fragments of meaningless but minimally coordinated behaviour can be expressed by patients in the vegetative state. The following discussion describes the clinical course and fragments of behaviours of three patients and briefly summarizes the results of metabolic studies that hint at the underpinnings of their unique expressions.

The descriptive concept of the persistent vegetative state has been extensively validated by additional reports since 1972. Table 1 lists the standard clinical criteria. Positron emission tomographic (PET) studies in several laboratories (Levy *et al.* 1987; DeVolder *et al.* 1990; Tommasino *et al.* 1995) have consistently identified average cerebral oxidative or glucose metabolism in PVS patients as lying between 35% (post-anoxic) and 56% (post-traumatic). These average rates are similar to those found during deep surgical anaesthesia (Blacklock *et al.* 1987). Selected small areas of higher function in restricted areas of the cerebral hemispheres in some PVS patients have reached glucose consumption rates of as high as 71% of normal (Tommasino *et al.* 1995), but these still are well below normal. However, no evidence of functional departures from standard vegetative behaviour have been described previously in patients showing these metabolic outliers recorded by PET scanning.

We selected three patients from a group of 50 PVS patients, who were diagnosed as being in a persistent vegetative state by all existing clinical criteria; all three exhibited unanticipated, spontaneous movements. These patients, without any evidence of conscious awareness, have expressed randomly brief, isolated and stereotypically reiterated fragments of organized behaviour. The individual patterns were unique for each patient and included three different forms: the first consisted of short bursts of simple, non-goal directed, isolated words, but no phrases; the second included spontaneous, purposeless, coordinated movements of body parts vaguely resembling but different from chorea, and the third consisted of

Table 1. *Clinical criteria of the persistent–permanent vegetative state*

time durations
one month, if persistent more than one year, almost always permanent:
no cognition: consistent responses to linguistic, symbolic or mimetic instruction are absent
no semantically meaningful sounds or goal-directed movements
no sustained head-ocular pursuit activity
usually or often preserved
brain stem and autonomically controlled visceral functions: homeothermia; osmolar homeostasis; breathing; circulation; gastrointestinal functions
pupillary and oculovestibular reflexes usually remain and are accentuated
brief, inconsistent shifting of head or eyes toward new sounds or sights may occur
smiles, tears or rage reactions may occur either spontaneously or to non-verbal sounds
reflex postural responses to noxious stimuli remain

major rage outbursts in response to being touched, but with no evidence of possessing targets for the violent, brief, autonomically charged, motor explosions.

All patients were studied in the research unit of Cornell–New York Hospital's NIH-supported Clinical Research Center (CRC) for 4–5 consecutive days. Under the study protocol each patient underwent 24 to 36 hours of EEG and videotaping, magnetic resonance imaging (MRI 1.5T) and resting metabolic brain mapping using fluorodeoxyglucose-PET (FDG-PET) recorded at Memorial Sloan-Kettering Cancer Center. Further functional brain imaging in each patient was done with magnetoencephalographic analysis (MEG, Magnes, Whole-head-148 channel BTi) at the New York University Center for Neuromagnetism.

## 2. PATIENTS

*Patient 1.* A 49-year-old woman, previously employed as a nurse until age 29, suffered three successive deep cerebral haemorrhages emanating from an inoperable arteriovenous malformation at the base of the cerebrum. Bleeding from the malformation destroyed the right basal ganglia and thalamus, and also severely damaged the right cerebral hemisphere as well as a large portion of the left thalamus. She has remained vegetative for the ensuing 20 years in all dimensions, except that at intervals of 24–72 hours or so, she is heard to randomly express simple, reiterated words: 'down, down, down' or sometimes repeated common four-letter expletives. At most, her total articulated vocabulary may include 4–5 different words, spoken in either English or Spanish. None have descriptive or object-related content. Physically, she has randomly scattered, relatively short sleep–wake cycles, bilateral mildly spastic hemipareses, no non-reflexive or purposeful responses to noxious stimuli and prominent, oculocephalic reflexes. Medical/nutritional complications remain absent.

*Patient 2.* A 52-year-old, moderately overweight man with a history of sleep apnoea developed respiratory

decompensation and arrest six hours following elective cosmetic surgery. He subsequently remained unresponsive for 48 hours but after awakening was bewildered and responded only to one-step commands. A week later, he relapsed into eyes-closed coma and remained in that state for another eight weeks. For the next four months he remained classically vegetative. Six months after onset of illness, he spontaneously developed episodic, coordinated but purposeless, relatively slow movements involving the head and all four extremities. These lasted for several hours each day. No evidence that he was aware of self or capable of cooperative interaction could be obtained. Throughout both phases of behaviour he showed mild bilateral spasticity plus abnormal oculocephalic and somatosensory reflexes, both of which had been present since the onset of his prolonged comatose period. No evidence of cognitive awareness emerged during the entire period following the original relapse.

*Patient 3.* A 38-year-old man has been vegetative for over seven years following closed head trauma resulting from a motor vehicle accident. Past medical records are incomplete, but he is described by his family as having no responsiveness other than that described below to environmental stimuli throughout this time. For the past seven years he has been in a nursing home wherein the highly discerning staff has found no evidence of verbal or appropriate behavioural interaction. Presently, he shows no hint of cognitive responses to outer stimuli or awareness of inner intentions. He suffers from a double hemiplegia. He has brisk, reflexive oculocephalic movements (plus severe blepharospasm) and he makes no selectively appropriate responses to any kind of cognitive stimulus. When anyone makes a loud noise or attempts to examine, feed or bathe him, he immediately expresses clenched-teeth, rigid extremities, and produces a high pitched noise that sounds like a maximal, screaming rage. During these attacks his skin colour flushes, and his blood pressure rises. The entire scenario resembles the 'sham rage' attacks obtained many years ago by Walter B. Cannon (1927) in cats following pre-collicular transection of the brain stem. Conversely, if gentle sounds, soothing voices or music are played in his environment he quiets down and allows himself to receive nursing care and feedings. Despite years of effort by therapists of several kinds, he has never become able to condition his behaviour to express any self-awareness or to adapt to his personal needs.

### 3. TECHNICAL RESULTS

In all three patients, we registered cerebral anatomy as defined by MRI scans, patterns of radioactive glucose uptake measured by PET scanning and analyses of equivalent current dipoles from magnetoencephalography (detailed PET measurements and MEG results will be reported independently). Informed consent was obtained from the patients' families for all procedures. We used a GE Advanced PET camera in order to measure baseline cerebral metabolic rates using Phelps *et al.*'s (1979) FDG autoradiographic method. Patients fasted for at least six hours prior to the study. Plasma glucose values were obtained from a temporary arterial line. The patients were studied at rest in a supine state with eyes open.

Regions of interest (ROIs) were drawn by hand on core-registered MRI–PET images.

In patient 1 who expresses words, but lacks all other evidence of mind, MRI images disclose in the right hemisphere a nearly complete absence of the thalamus and the basal ganglia. Inferior frontal, temporal and parietal cerebral areas are severely damaged whereas more dorsal planes show infarction in the distribution of the medial branch of the middle cerebral artery. No part of the right hemisphere had a level of metabolic activity greater than 40% of normal. On the left side, the postero-inferior thalamus appears severely damaged, as do the orbito-frontal and occipital areas. The metabolic rate of the left thalamus was identified at below 50% of normal. By contrast, remaining structures in the left basal ganglia, especially the caudate area, the left frontal insular cortex, Broca's area and the lateral temporal–parietal regions metabolized glucose at a level of 50–66% of normal. Although all the above studies were conducted during wakefulness we were unable to perform any of them during the patient's random and brief episodes of speech. (Detailed functional imaging results and discussion of this patient appears elsewhere (Schiff *et al.* 1998).)

In patient 2, PET scanning indicated that all cerebral areas functioned at an anaesthesia-like very low level, averaging 30% of normal controls. The low level is comparable to those found in other post-anoxic vegetative patients by Levy *et al.* (1987), DeVolder *et al.* (1990) and Tommasino *et al.* (1995). The paramedian and prefrontal frontal lobe areas, basal ganglia, scattered temporal areas, the medial thalamus, the pontine-mesencephalic tegmental reticular area and parts of the cerebellum demonstrated moderately higher degrees of metabolism ranging between 30–40% of consumption in normal controls (figure 1). The selective activation of these areas suggests that bilateral cortical and subcortical loops of motor activation remain that account for the unusual continuous movements exhibited by this patient.

The results of patient 3's PET scan again indicated that cerebral areas functioned at a very low level, averaging 30% of normal controls. Several right hemisphere regions showed slightly higher levels of metabolism including the temporal parietal cortex, prefrontal and frontal cortex, and anterior basal ganglia (figure 2). These areas represent the expressed reciprocal of the lesions that typically produce aprosodia (Ross 1997). The notably adverse response of this patient to touch and his quieting reaction to music suggests the expression of cortical and subcortical activity arising from brain regions possessing abnormally low metabolic rates that nevertheless possessed higher rates than the remaining cerebrum.

### 4. CONCLUSIONS

The heretofore not described observations of coordinated but stereotyped behaviour in these three PVS patients demonstrate that isolated modular operations in the damaged human brain may be expressed in the absence of consciousness. The dissociation of these fragments of function from consciousness helps to confirm the fundamental observation of the vegetative state (Jennett & Plum 1972); i.e. consciousness is not merely a

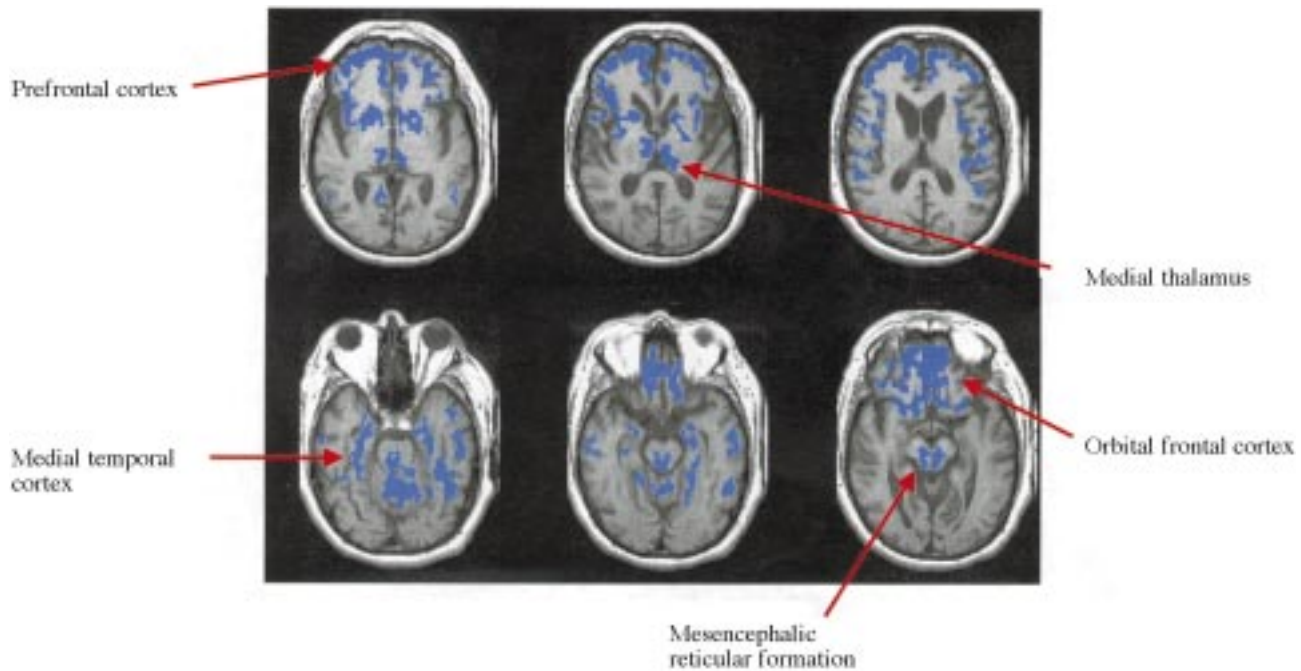


Figure 1. FDG-PET regions of interest for patient 2 are displayed in blue on coregistered MRIs. All areas express  $>30\%$  of normal glucose metabolism to a maximum of  $40\%$  of normal, remaining brain regions demonstrate  $<30\%$  of normal metabolism. Higher metabolism is evident in bilateral prefrontal and orbitofrontal cortices and posterior thalamic and reticular structures.

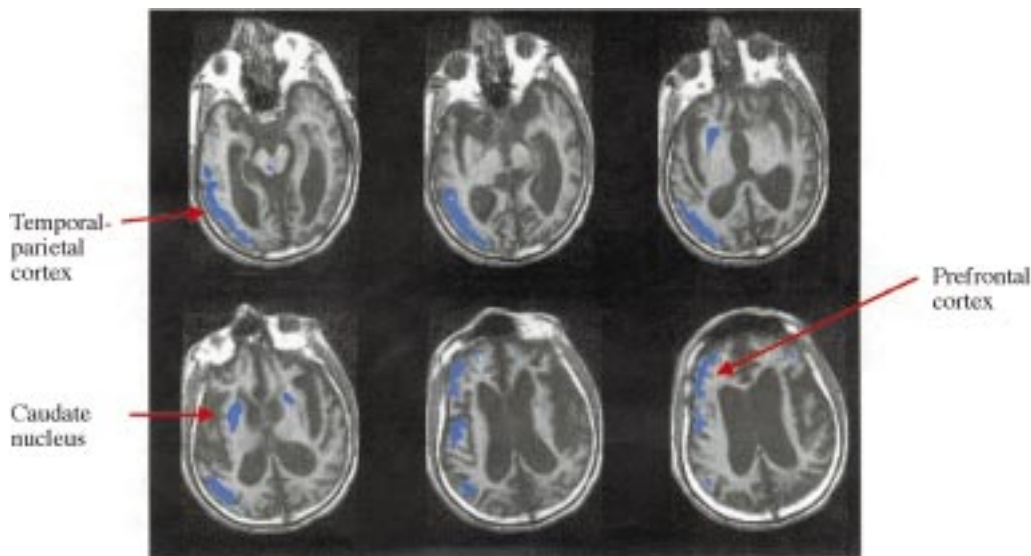


Figure 2. FDG-PET regions of interest for patient 3 are displayed in blue on coregistered MRIs. All areas express  $>30\%$  and a maximum of  $40\%$  of normal metabolism, remaining brain regions demonstrate  $<30\%$  of normal metabolism. Regions of higher metabolism include the temporal-parietal and prefrontal cortices of the right hemisphere and the anterior basal ganglia. Note the marked atrophy of the brain on the MRI image as indicated by the dilation of the third and lateral ventricles, and widening of cortical sulci.

quantitative matter of degree but in fact is qualitatively absent in the vegetative state. Furthermore, the pairing of the vegetative state with the expression of various modular brain functions does not by itself confer any additional degree of 'consciousness'.

Despite their expressions of isolated behaviour described above, none of these three patients have provided evidence of any awareness or interactive behaviour either over the course of study or during extended and careful efforts of rehabilitation and medical supervision that have lasted months or years without changing. These patients differ from the newly coined 'minimally conscious state' (Giacino & Kalmar 1997), in that no hint of purpose, intent or object awareness could at any time

be delineated. Unlike severe dementia or acute delirium none of the three expressed even a glimmer of awareness of the self or the environment.

The unique observations of repeated, singularly stereotypic but cognitively meaningless behavioural acts in these three persons have not previously been reported in association with persistent or permanently vegetative states. No other action or reaction in these patients suggested that their unique motor phenomena was engendered by self-aware intention or purpose. The uttered expletives in patient 1 and the semi-choreiform movements observed in patient 2 occurred randomly in time and always during wakefulness. No other spontaneous behavioural expressions marked their closely observed

days in either the hospital or nursing homes. The third expressed his organized activity only in response to external stimulation. None of the three patients expressed any novel or accentuated actions in the presence of family, care-givers, extraneous abrupt sounds, environmental noise or temperature changes. Put succinctly, the stereotypical, non-directed fragments of semi-coordinated behaviour in these three persons bore no resemblance to the seemingly object-directed but severely limited behaviour that characterizes the minimally aware/conscious state identified either by Rancho scores (Hagen *et al.* 1972) or other criteria (Giacino & Kalmar 1997). Nor does the randomly expressed behaviour in these three patients resemble, in any way, the locked in state, a condition in which illness or accident disconnects a cognitively functional cerebrum from the peripheral mechanisms that express somatomotor activity. As Zeki and other reporters (this issue) indicate in this Symposium, cerebral mechanisms of consciousness can be selectively vulnerable to focal injury of critical visual or verbal cognitive modules that normally contribute to the individual's conscious state. The patients described in this short report however, suffer from an opposite condition: they have lost all conscious awareness but, nevertheless, they have selectively and individually retained the isolated capacity to express the singular workings of (i) a modular fraction of verbal utterance, (ii) a module of repetitious, coordinated somatomotor activity, or (iii) a module of unsuppressed, precognitive emotion. The findings lead us to conclude that consciousness itself may be dissociated from minimal wakeful behaviour. Other clinical examples, such as the unconsciously generated behavioural automatisms of partial complex seizures, also suggest that self-aware consciousness represents an integrative neurophysiological process, and not just an above-threshold property of multi-modular cerebral expression.

We acknowledge the careful help and assistance with PET imaging of Brad Beattie, Diana Moreno and Dr Ronald Blasberg. We further thank Dr Carolyn McCagg and Dr Joseph Giacino for their assistance in the evaluation of patients 2 and 3. These studies were supported by the Charles A. Dana Foundation, the NIH Clinical Research Center and the Annie Laurie Aitken Charitable Trust.

## REFERENCES

- Bichat, M.-F.-X. 1800 *Recherches physiologiques sur la vie et la mort*, pp. 1–189. Paris: Brosson Gabon.
- Blacklock, J. B., Oldfield, E. H., Di Chiro, G., Tran, D., Theodore, W., Wright, D. C. & Larson, S. M. 1987 Effect of barbiturate coma on glucose utilization in normal brain versus gliomas. Positron emission tomography studies. *J. Neurosurg.* **67**, 71–75.
- Cannon, W. B. 1927 *Bodily changes in pain, hunger, fear and rage* (2nd edn). New York and London: D. Appleton & Co.
- Cannon, W. B. & Britton, S. W. 1925 Studies on the conditions of activity in endocrine glands, XV pseudoaffective medullary-adrenal secretion. *Am. J. Physiol.* **72**, 283–294.
- DeVolder, A. G., Goffinet, A. M., Bol, A., Michel, C., de Barsey, T. & Laterre, C. 1990 Brain glucose metabolism in postanoxic stroke. *Arch. Neurol.* **47**, 197–204.
- Giacino, J. & Kalmar, K. 1997 The vegetative and minimally conscious states: a comparison of clinical features and functional outcome. **12**, 36–51.
- Hagen, C., Malkmus, D. & Durham, P. 1972 *Levels of cognitive functioning*. Downey, CA: Rancho Los Amigos Hospital.
- Jennett, B. & Plum, F. 1972 Persistent vegetative state after brain damage. A syndrome in search of a name. *Lancet* **1**, 734–737.
- Levy, D. E., Sidtis, J. J. & Rottenberg, D. A. 1987 Differences in cerebral blood flow and glucose utilization in vegetative versus locked-in patients. *Ann. Neurol.* **22**, 673–682.
- Multisociety Task Force on PVS 1994 Medical aspects of the persistent vegetative state. Part 1. *N. Engl. J. Med.* **330**, 1499–1508.
- Phelps, M. E., Huang, S. C., Hoffman, E. J., Selin, C., Sokoloff, L. & Kuhl, D. E. 1979 Tomographic measurement of local cerebral glucose metabolic rate in humans with (F-18) 2-fluoro-2-deoxy-D-glucose: validation of method. *Ann. Neurol.* **6**, 371–388.
- Ross, E. D. 1997 The aprosodias. In *Behavioural neurology and neuropsychology* (ed. T. E. Feinberg & M. J. Farah), pp. 699–710. New York: McGraw-Hill.
- Schiff, N., Ribary, U., Plum, F. & Llinas, R. 1998 Words without Mind. *J. Cog. Neurosci.* (Submitted.)
- Timme, W., Davis, T. K. & Riley, H. A. (eds) 1928, 1930 The vegetative nervous system; an investigation of the most recent answers. In *Proc. Assoc. Res. Nerv. Mental Dis.*, vol. IX. Baltimore, MD: Williams & Wilkins.
- Tomassino, C., Grana, C., Lucignani, G., Torri, G. & Ferruccio, F. 1995 Regional metabolism of comatose and vegetative state patients. *J. Neurosurg. Anesth.* **7**, 109–116.

BIOLOGICAL  
SCIENCES



THE ROYAL  
SOCIETY

PHILOSOPHICAL  
TRANSACTIONS  
OF

BIOLOGICAL  
SCIENCES



THE ROYAL  
SOCIETY

PHILOSOPHICAL  
TRANSACTIONS  
OF